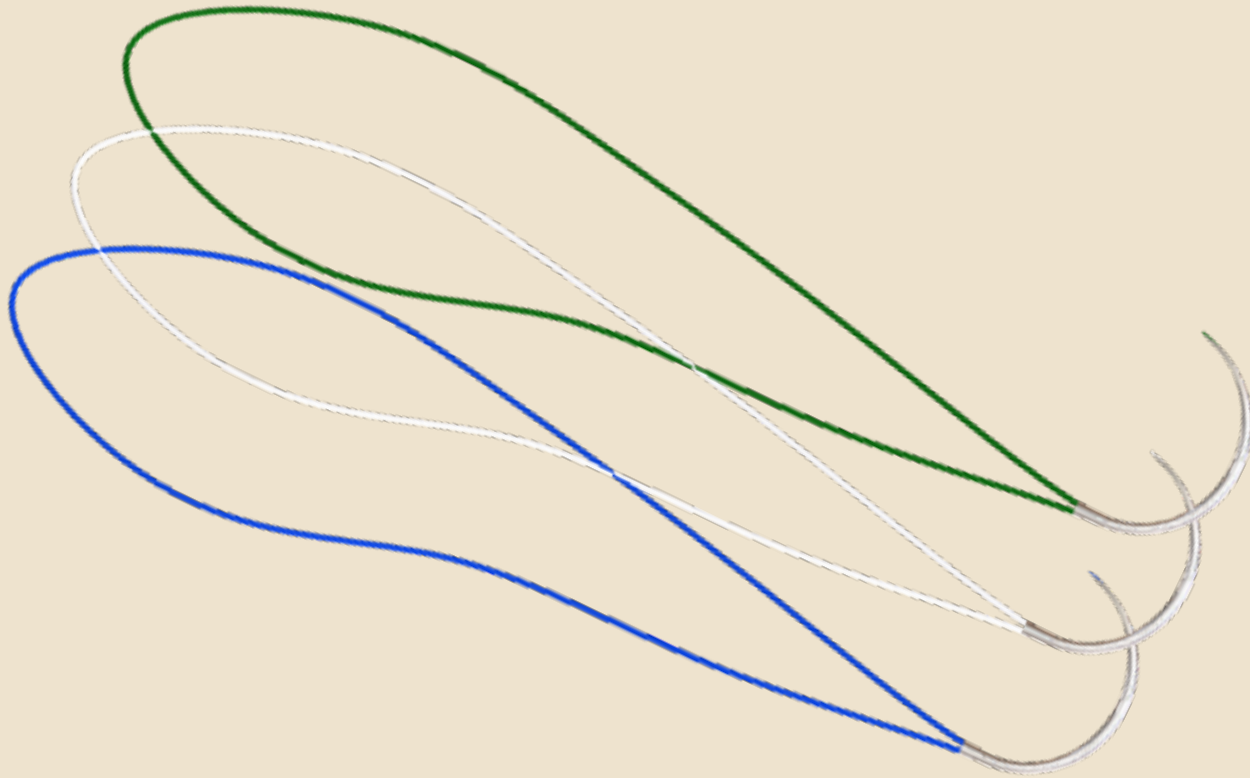
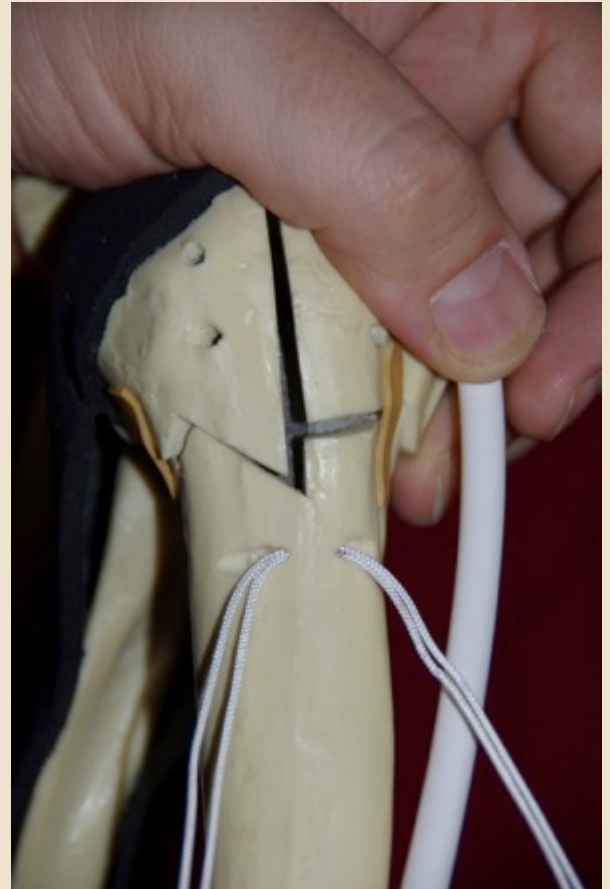
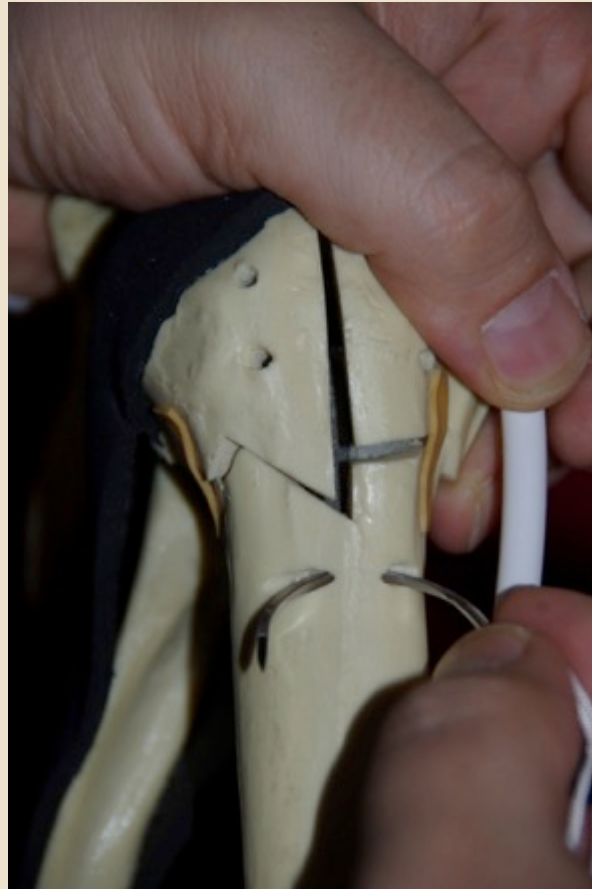
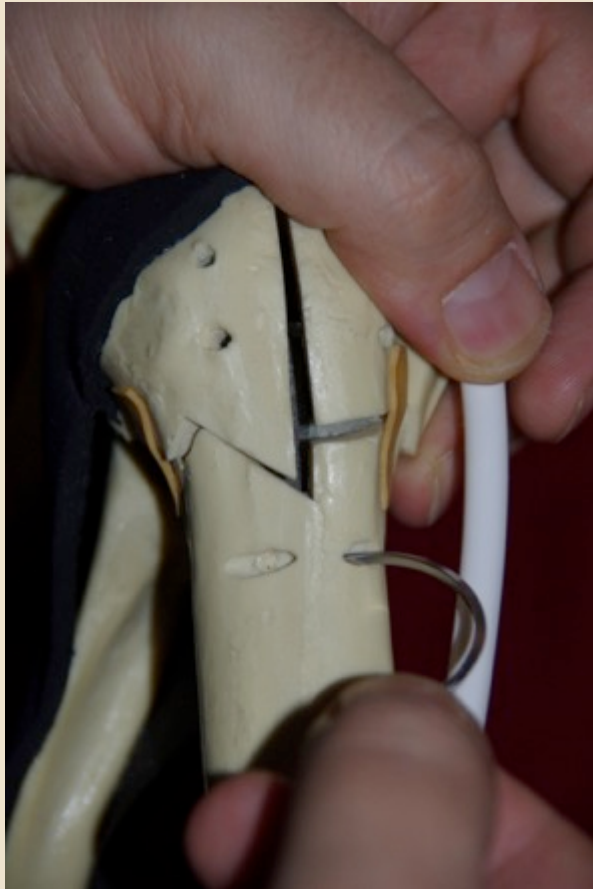


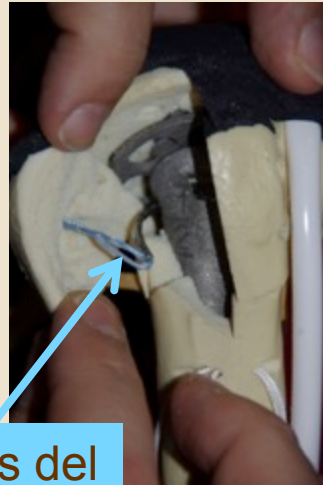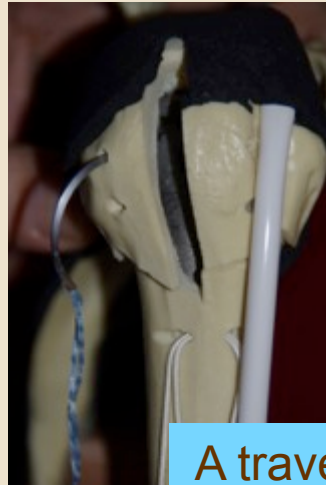
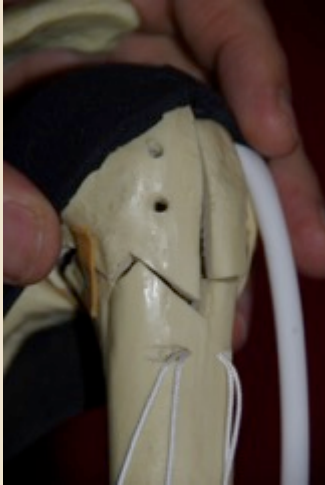SUTURA DE LAS TUBEROSIDADES CON « SMARTLOOP »



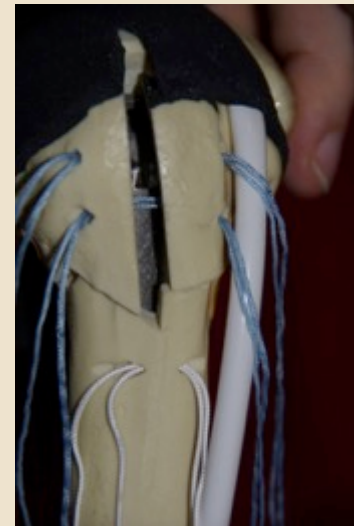
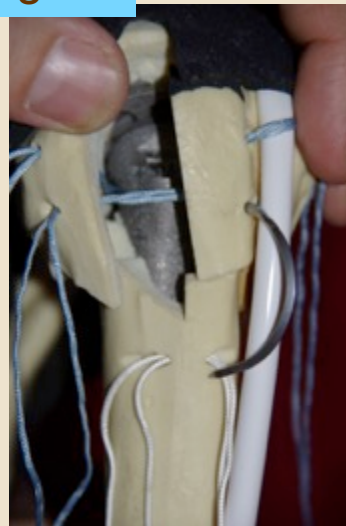

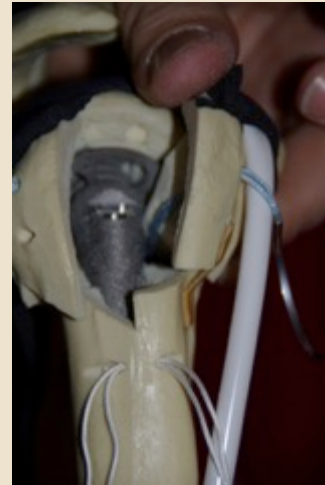
PREPARACIÓN DE LA ATADURA N/S



PREPARACIÓN DEL TUBÉRCULO MAYOR



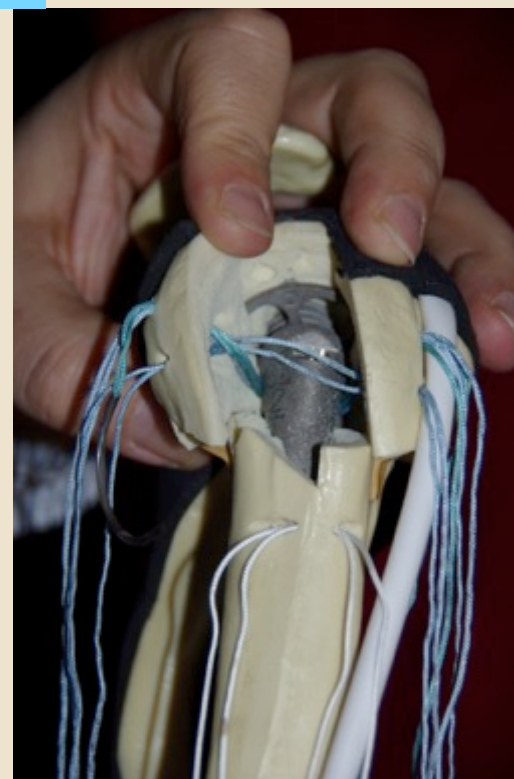
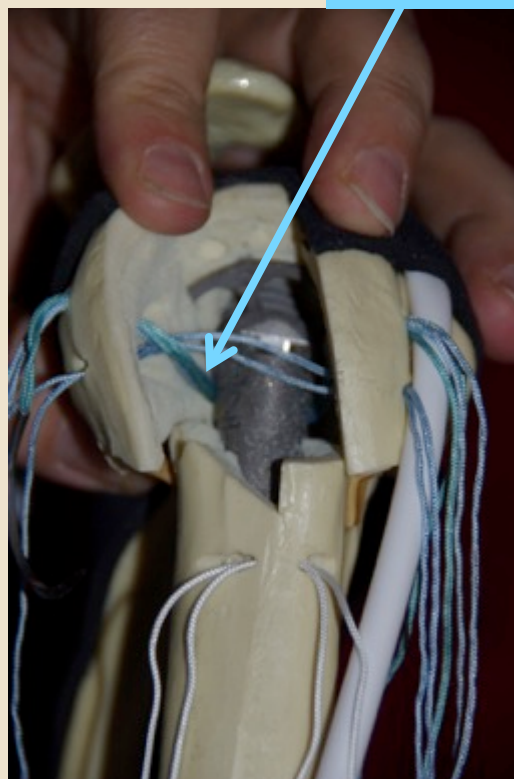
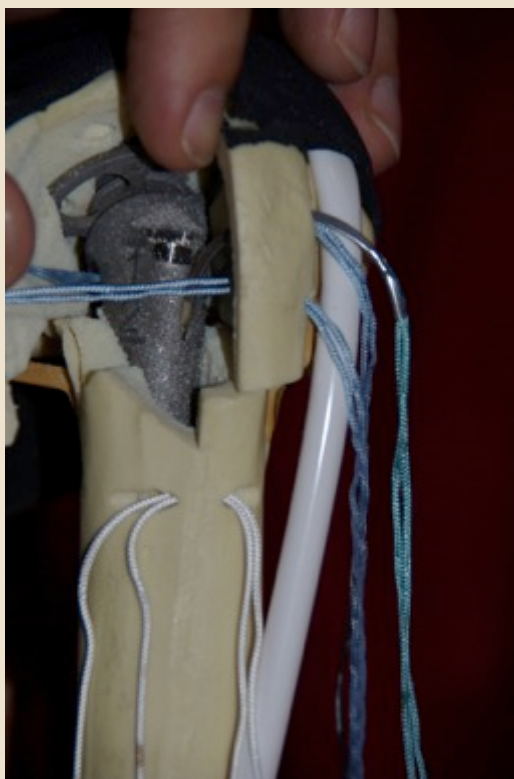A través del
vástago



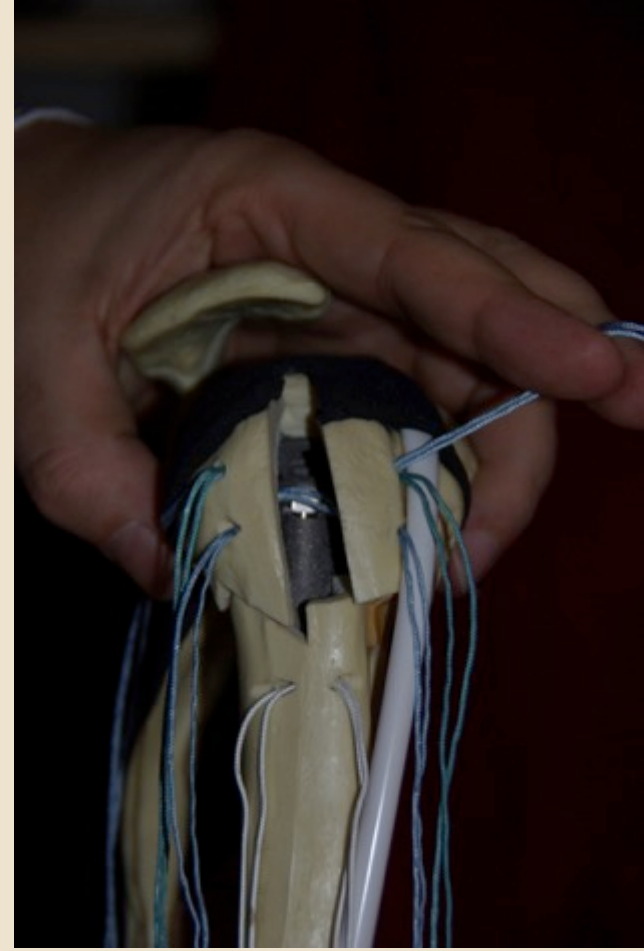
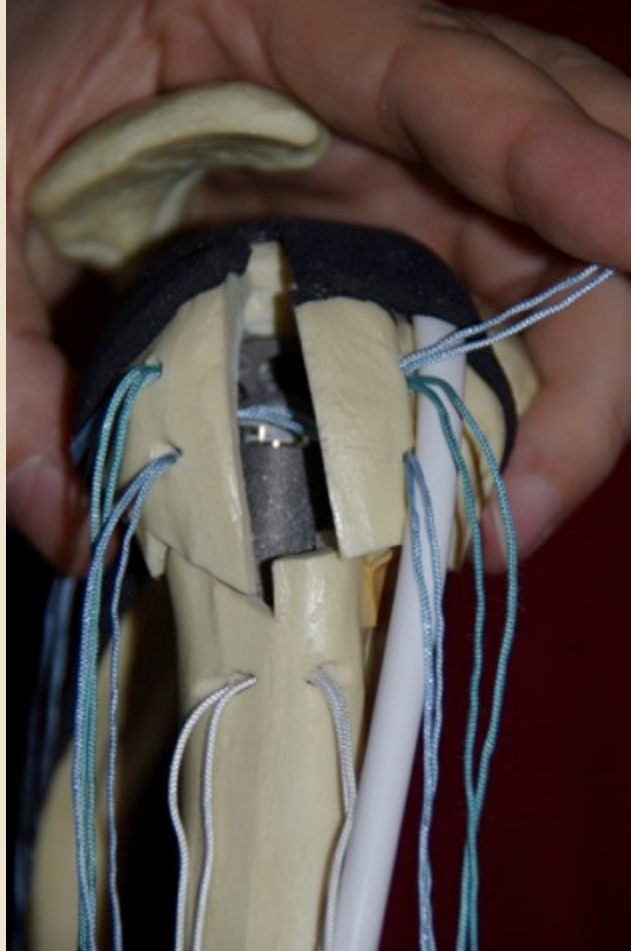
PREPARACIÓN DEL TUBÉRCULO MENOR



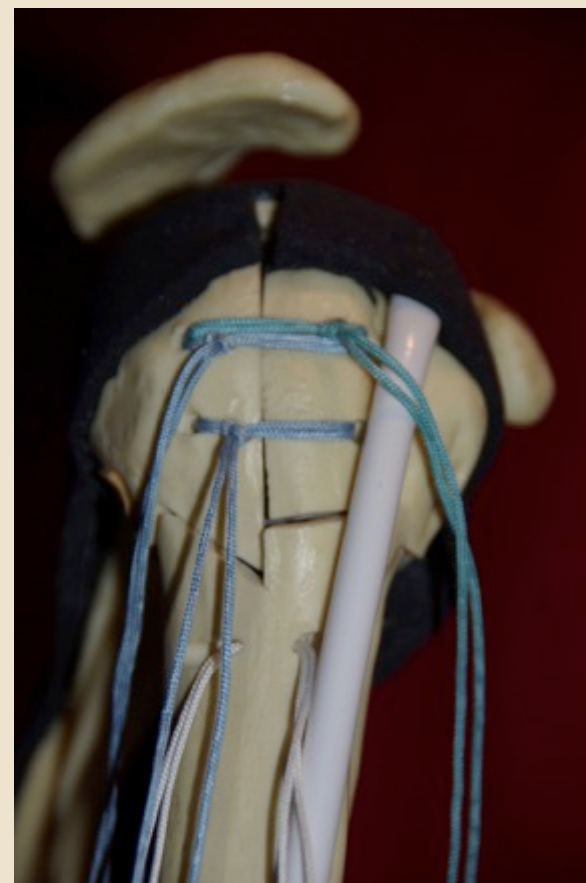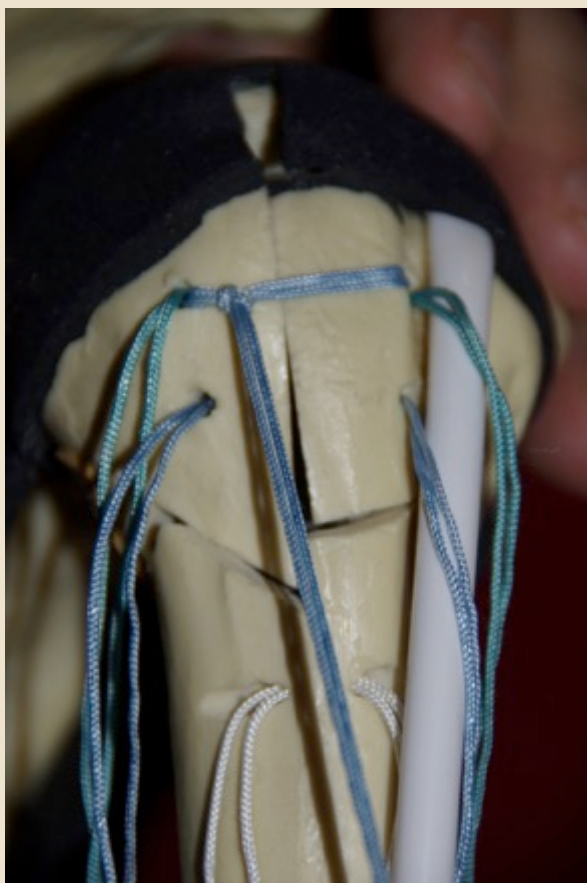A través del
vástago



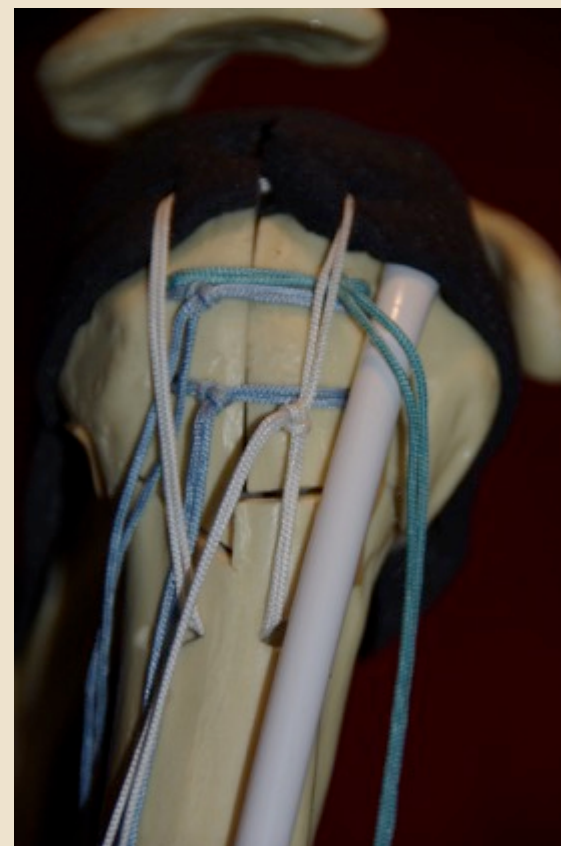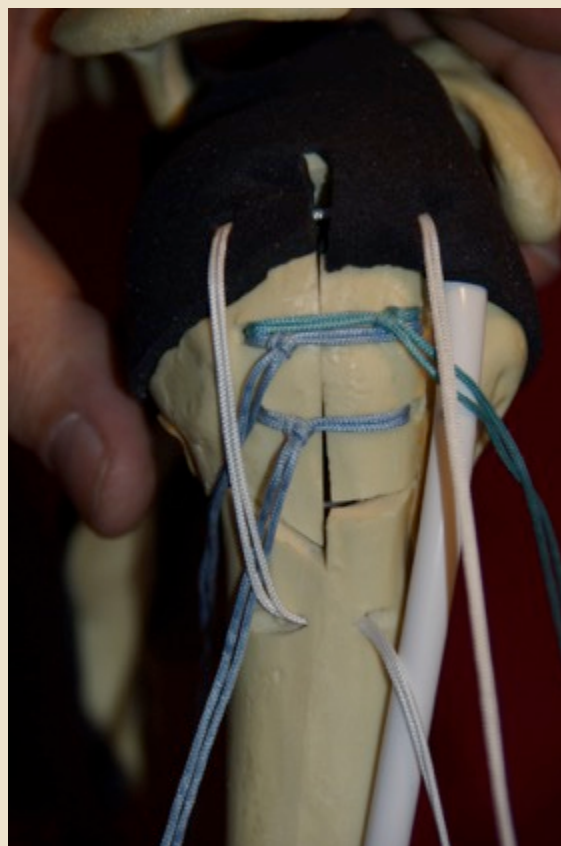
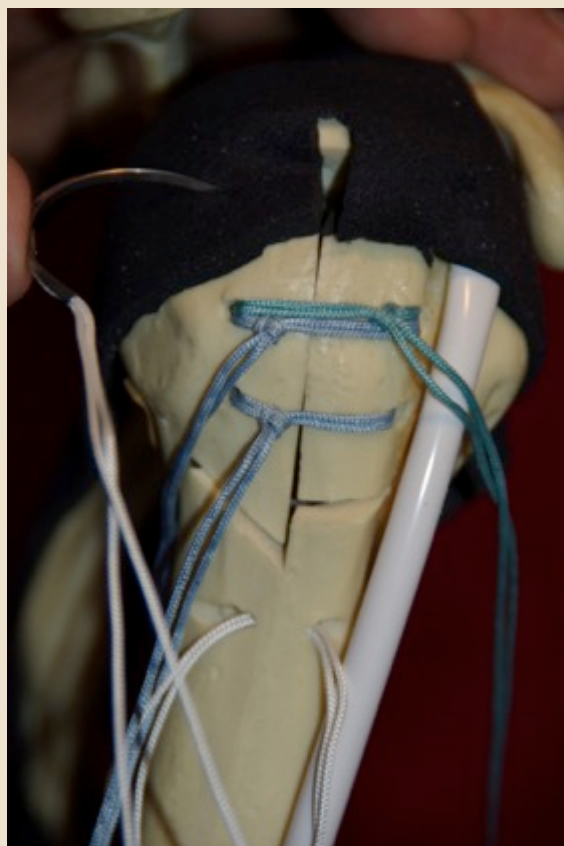
UBICACIÓN DE SUTURAS POR COLOR



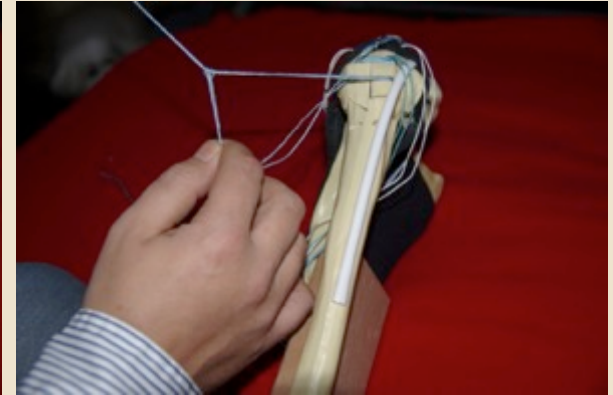
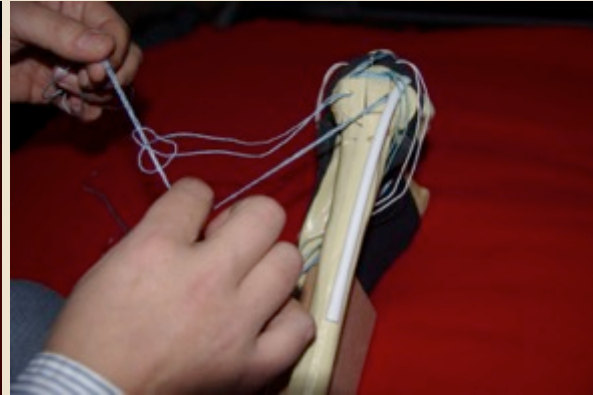

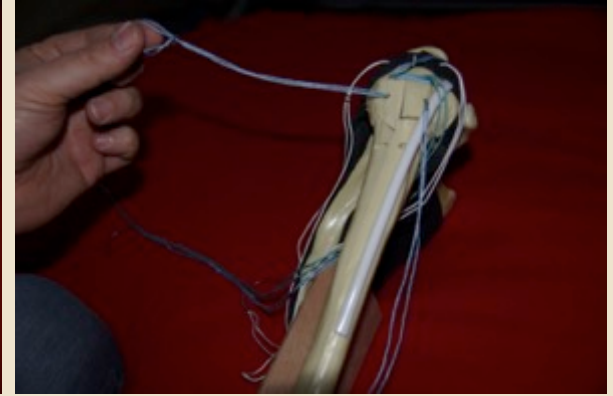
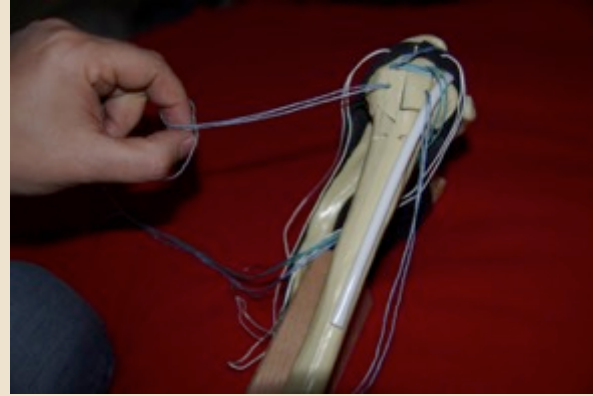

RELACIÓN DE LOS NUDOS EN LAS TUBEROSIDADES



ATADURA CON NUDO N/S



IMPLEMENTACIÓN DEL NUDO



IMPLEMENTACIÓN DEL NUDO

